

Case report

## Laparoscopic Injection of Methylene Blue to Discriminate Cyst from Calyceal Diverticulum

Seyed Mohammad Kazem Aghamir<sup>1</sup>, Fatemeh Khatami<sup>1</sup>, Hamidreza Zia<sup>1\*</sup>

<sup>1</sup>Urology Research Center, Tehran University of Medical Sciences, Tehran, Iran

### HIGHLIGHTS

- Renal cysts are sacs of fluid with a thin wall usually with no symptoms and have no connection to the renal calyx.
- Methylene blue can prove that there is no leaking of renal calyx through catheter.
- Methylene blue can be considered for distinguishing cyst from calyceal diverticulum.

### ARTICLE INFO

Document type: Case report

Receive Date: 15 June 2019

Accept Date: 16 July 2019

Available online: 12 August 2019

DOI: 10.22034/AU.2020.221836.1008

©2019 Transresurology. All right reserved.

### ABSTRACT

#### Introduction

Renal cysts are sacs of fluid with a thin wall usually with no symptoms and have no connection to the renal calyx. Another renal lesion that can be misdiagnosed with cysts is the calyceal diverticulum with a connection to the renal calyx. The new approach of laparoscopic injection of methylene blue can help the surgeon to distinguish renal cysts from calyceal diverticulum in a patient with no double J (Dj/JJ).

#### Case presentation

A 52-years patient with a 15 cm lesion underwent laparoscopic surgery of a renal cyst. Surgery was done in the flank position and the peritoneoscopy was performed after cyst reveal. At the bottoms of the cyst, several small cysts were observed so we inject methylene blue to make it clear this lesion was exactly cysts, not calyceal diverticulum. When it was proven that there is no leaking of blue color to the renal calyx through the catheter. The cyst was revealed and was removed and sent for pathology.

#### Conclusions

In our study, the laparoscopic injection of methylene blue indicated no connection with renal calyx so the lesion is renal cysts. So it can be a new approach for distinguishing cyst from calyceal diverticulum.

**Keywords:** Renal Cyst; Calyceal Diverticulum; Laparoscopy

#### Introduction

The kidney is one of the most common sites for the cyst in the body (prevalence about 5%). Kidney cysts are sacs of fluid in the kidneys which are characterized as “simple” cysts with a thin wall (1). They become common as people getting old and are with no symptoms or harm. Because they often don’t cause symptoms are incidentally found by renal imaging including computed tomography (CT) and ultrasonography (2, 3). The prevalence, number, and size of renal cysts are greater in men compared to women and are connected to age, hypertension, and smoke

\*Corresponding Author: Hamidreza Zia

Email: [ziahamidreza@gmail.com](mailto:ziahamidreza@gmail.com)

Address: Urology Research Center (URC), Sina Hospital, Hassan Abad Sq., Tehran, Iran

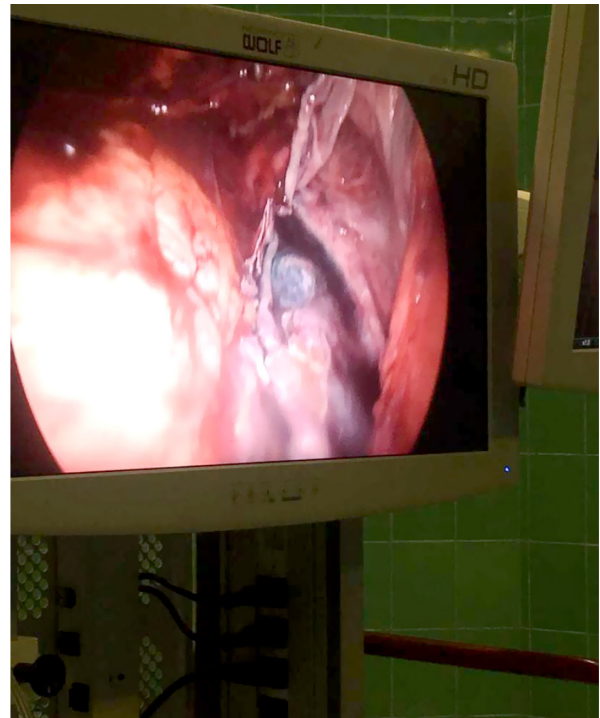
(4). Most renal cysts (sporadic, acquired, or hereditary) arise from parts of nephrons or collecting ducts, while multicystic dysplasia arises before the formation of nephrons (5).

The calyceal diverticulum or pyelocalyceal diverticulum is a urine-containing cystic cavity within the renal parenchyma lining by transitional epithelium and surrounded by muscularis mucosae which are connected to the collecting system (6). The majority of calyceal diverticula can be diagnosed by ultrasound and intravenous urogram (IVU) and retrograde studies are required to confirm calyceal diverticula diagnosis. More often than not, the diverticulum is misdiagnosed as a complex cyst or even as a neoplasm. The treatment strategy is completely dependent on the exact diagnosis of cysts or calyceal diverticula and it is critical to discriminate cysts from calyceal diverticula. In some patients, there is not possible to place a double J stent because of the skeletal situation of patients or make the surgery duration shorter. In the current study, we use laparoscopic methylene blue in cysts to ensure there is no contact with the pyelocalyceal system.

### **Case presentation**

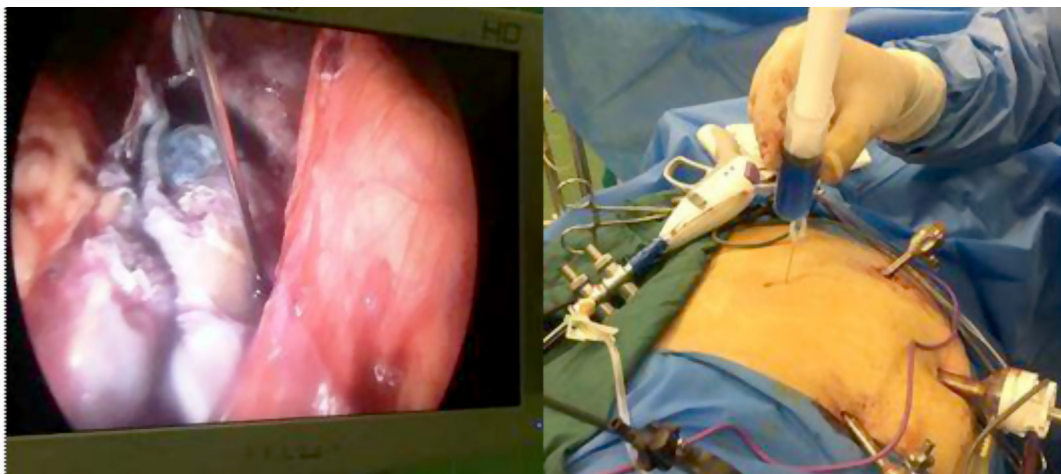
A 52-year woman referred to Sina hospital complaining about vague right flank pain and heavy feeling. Her diagnosis was a large flank cyst. She had no family examination, no history of surgery, and no other illness. Abdominal and pelvic computed tomography with and without contrast and simple culture indicated to the 15 cm cyst.

We selected this case and all steps of our study were completely adhere to CARE guidelines. She was the candidate for surgery but there was no certain diagnosis between renal cysts and calyceal diverticulum. In the flank position and through the open access the trocar 15 was embedded. Then peritoneoscopy was performed and 2 trocars 5 were implanted. The colon with strong




**Figure 1.** Reveal cyst

adhesion was fully medialized. Now the cyst was exposed (Figure 1). The needle was inserted through the skin into the large cyst and sterile methylene blue was injected (Figure 2). The cyst was complete with blue color. The catheter was checked to see whether the blue color enters the urine stream or not (Figure 3). Fortunately, it was completely clear and its roof was unroofed. At the bottoms of the cyst, several small cysts were observed so we inject methylene blue as mentioned above and check for urine color, after approved that the lesions are cyst, the cyst wall was removed. After six weeks and six months, the patient report the satisfying result of surgery with no vague right flank pain or cyst recur in follow-up sonography.



**Figure 2.** Injection of methylene blue



**Figure 3.** Check of urine color

### Discussion

The exact diagnostic between renal cysts and calyceal diverticulum is problematic. In the current study, we use a new approach for antegrade detection by using methylene blue color. In fact, for renal cystic treatment the percutaneous aspiration, with or without sclerotherapy can be the lucrative minimally invasive option with very high recurrence rates (up to 90%) (7, 8).

Calyceal diverticulum mimics solitary or multiple fluid-filled spaces located within one or both kidneys (9, 10). They are mostly placed in the upper pole of the kidney in the connection with the minor calyx so their treatment strategy is different from renal cysts. Surgical ablation of calyceal diverticula by percutaneous endoscopy, laparoscopy, and ureteroscopy has fundamentally taken the place of both extracorporeal shock wave lithotripsy (ESWL) and open surgical fulguration in almost all cases of diverticular cavities (11). In our case, it was important to know it is calyceal diverticula or pyelogenic cysts. The typical renal cyst looks transparent and is black and blue in some areas so injecting methylene blue into the cyst can aid the surgeon to identify the cyst wall more accurately (12). Methylene blue is a fluorophore and a heterocyclic aromatic compound with a diameter of 1.43 nm, 320Da, with an excitation peak of 670 nm and an emission peak of 690 nm (13). It was reported by Roberts and his colleagues that for parenchymal cysts, the methylene blue injection through the ureteral catheter can make it clear there is no communication with the collecting system (14). In 2018, Wang and his colleagues represented a modified method for easily locating cystic wall by methylene blue injection

via percutaneous renal cyst puncture in the flexible ureteroscope (15). In our study, the needle was inserted through the skin into the small cysts and methylene blue injection indicated no connection with renal calyx so the lesion is renal cysts.

### Conclusions

In some patients, there is not possible to place a double J stent because of the skeletal situation of patients or make the surgery duration shorter. Also, double J has its complication and difficulties. Laparoscopic injection of methylene blue can be a new approach for distinguishing a cyst from a calyceal diverticulum in such cases.

### Authors' Contributions

SMKA was the principal surgeon and who suggest this novel method, HRZ was the surgeon, and FKH wrote the manuscript.

### Acknowledgments

Special thanks to Urology Research Center (URC), Tehran University of Medical Sciences, Tehran, Iran.

### Conflict of interest

All authors claim that there is no competing interest in this case report of surgery.

### Funding

There was no founding.

### Ethics statement

All authors ensured our manuscript reporting adheres to CARE guidelines for reporting of case reports.

### Data availability

Data will be provided by the corresponding author on request.

### Abbreviations

CT	Computed tomography
Dj	Double J
ESWL	Extracorporeal shock wave lithotripsy
IVU	Intravenous urogram

## References

1. Terada N, Ichioka K, Matsuta Y, Okubo K, Yoshimura K, Arai Y. The natural history of simple renal cysts. *The Journal of urology*. 2002;167(1):21-3.
2. Caglioti A, Esposito C, Fuiano G, Buzio C, Postorino M, Rampino T, et al. Prevalence of symptoms in patients with simple renal cysts. *BMJ: British Medical Journal*. 1993;306(6875):430.
3. Bisceglia M, Galliani CA, Senger C, Stallone C, Sessa A. Renal cystic diseases: a review. *Advances in anatomic pathology*. 2006;13(1):26-56.
4. Mensel B, Kühn J-P, Kracht F, Völzke H, Lieb W, Dabers T, et al. Prevalence of renal cysts and association with risk factors in a general population: an MRI-based study. *Abdominal Radiology*. 2018;43(11):3068-74.
5. Bonsib SM. Renal cystic diseases and renal neoplasms: a mini-review. *Clinical Journal of the American Society of Nephrology*. 2009;4(12):1998-2007.
6. Middleton AW, Pfister RC. Stone-containing pyelocaliceal diverticulum: embryogenic, anatomic, radiologic and clinical characteristics. *The Journal of urology*. 1974;111(1):2-6.
7. Kilinc M, Tufan O, Guven S, Odev K, Gurbuz R. Percutaneous injection sclerotherapy with tetracycline hydrochloride in simple renal cysts. *International urology and nephrology*. 2008;40(3):609-13.
8. Hanna R, Dahniya M. Aspiration and sclerotherapy of symptomatic simple renal cysts: value of two injections of a sclerosing agent. *AJR American journal of roentgenology*. 1996;167(3):781-3.
9. Karmazyn B, Kaefer M, Jennings SG, Nirmala R, Raske ME. Caliceal diverticulum in pediatric patients: the spectrum of imaging findings. *Pediatric radiology*. 2011;41(11):1369-73.
10. Estrada CR, Datta S, Schneck FX, Bauer SB, Peters CA, Retik AB. Caliceal diverticula in children: natural history and management. *The Journal of urology*. 2009;181(3):1306-11.
11. Canales B, Monga M. Surgical management of the calyceal diverticulum. *Current opinion in urology*. 2003;13(3):255-60.
12. Hemal AK. Laparoscopic management of renal cystic disease. *Urologic Clinics of North America*. 2001;28(1):115-26.
13. Polom W, Markuszewski M, Rho YS, Matuszewski M. Usage of invisible near infrared light (NIR) fluorescence with indocyanine green (ICG) and methylene blue (MB) in urological oncology. Part 1. *Central European journal of urology*. 2014;67(2):142.
14. Roberts WW, Bluebond-Langner R, Boyle KE, Jarrett TW, Kavoussi LR. Laparoscopic ablation of symptomatic parenchymal and peripelvic renal cysts. *Urology*. 2001;58(2):165-9.
15. Wang Z, Zeng X, Chen C, Wang T, Chen R, Liu J. Methylene Blue Injection via Percutaneous Renal Cyst Puncture Used in Flexible Ureteroscopy for Treatment of Parapelvic Cysts: A Modified Method for Easily Locating Cystic Wall. *Urology*. 2019;125:243-7.

### Author (s) biosketches

**Aghamir SMK.**, Associate Professor., Urology Research Center, Tehran University of Medical Sciences, Tehran, Iran.

Email: [mkaghmir@tums.ac.ir](mailto:mkaghmir@tums.ac.ir)

**Khatami F.**, Ph.D., Urology Research Center, Tehran University of Medical Sciences, Tehran, Iran.

Email: [fatemehkhatami1978@gmail.com](mailto:fatemehkhatami1978@gmail.com)

**Zia H.**, MD., Urology Research Center, Tehran University of Medical Sciences, Tehran, Iran.

Email: [ziahamidreza@gmail.com](mailto:ziahamidreza@gmail.com)

### Copyrights

©2019 The author(s). This is an open access article distributed under the terms of the Creative Commons Attribution, which permits unrestricted use, distribution, and reproduction in any medium, as long as the original authors and source are cited. No permission is required from the authors or the publishers.



### How to cite this article

Aghamir SMK, Khatami F, Zia H. Laparoscopic Injection of Methylene Blue to Discriminate Cyst from Calyceal Diverticulum. *Translational Research In Urology*. 2019 Jul;1(1):8-11.

DOI: 10.22034/AU.2020.221836.1008

URL: [http://www.transresurology.com/article\\_106221.html](http://www.transresurology.com/article_106221.html)

