

Case report

Open Pyelolithotomy with Concurrent Percutaneous Nephrolithotomy in a Patient with an Ectopic Pelvic Kidney

Babak Javanmard¹, Seyyed Ali Hojjati^{2*}, Saba Faraji³, Maryam Garousi⁴, Amir Alinejad Khorram⁴

¹Department of Urology, School of Medicine, Shahid Beheshti University of Medical Sciences, Tehran, Iran

²Department of Urology, Shohada-e-Tajrish Hospital, Shahid Beheshti University of Medical Sciences, Tehran, Iran

³Department of Psychiatry, Roozbeh Hospital, Tehran University of Medical Sciences, Tehran, Iran

⁴Radiation Oncology Department, Iran University of Medical Sciences, Tehran, Iran

HIGHLIGHTS

- A large stone in an ectopic pelvic kidney is not a common case and therefore how to deal with it is important.
- Simultaneous surgery of two kidneys is not recommended, but it can be done in conditions such as bilateral obstruction or treatment costs.
- The abnormal position of the kidney and the possibility of damage to the surrounding organs as well as the size of the stone can make open surgery unavoidable.

ARTICLE INFO

Receive Date: 18 October 2022

Accept Date: 17 December 2022

Available online: 17 September 2023

DOI: 10.22034/TRU.2022.366280.1129

*Corresponding Author:

Seyyed Ali Hojjati

Email: sah_hojjati@yahoo.com

Address: Department of Urology, Shohada-e-Tajrish Hospital, Shahid Beheshti University of Medical Sciences, Tehran, Iran.

Introduction

The pelvic kidney is a rare anomaly with an incidence of about 1/2200 to 1/3000. Because most cases are asymptomatic, patients are usually not aware of their existence. Because of abnormal anatomical conditions

ABSTRACT

Introduction

The pelvic kidney is a rare anomaly that is prone to stone formation due to its abnormal position. Performing minimally invasive procedures can be risky because of the abnormal anatomy and uncertain blood supply of these kidneys.

Case presentation

In this study, we present a 43-year-old man who had an 8-cm stone in the right ectopic pelvic kidney concurrent with an obstructive stone in his left kidney. He underwent simultaneous open pyelolithotomy of the right pelvic kidney and percutaneous nephrolithotomy of the left kidney at one stage.

Conclusions

If possible, surgery for pelvic kidney stones should be performed using minimally invasive techniques. But in some cases, reasons such as the abnormal position of the kidney and the possibility of damage to the surrounding organs as well as the size of the stone can make open surgery unavoidable.

Keywords: Ectopic Kidney; Open Pyelolithotomy; Renal Stones

and aberrant rotation, these kidneys are prone to stone production (1). For treating nephrolithiasis in the pelvic kidney, like a normal kidney, techniques such as Open pyelolithotomy, laparoscopic-assisted percutaneous nephrolithotomy (PCNL); laparoscopic pyelolithotomy,

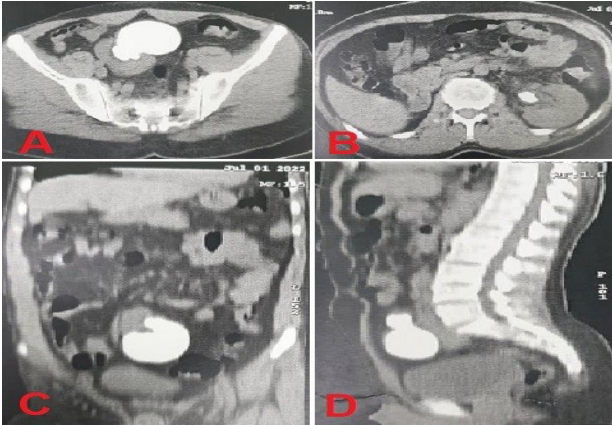


Figure 1. Abdominopelvic computed tomography (CT) scan without contrast. A 79 x 67 x 43-millimeter stone in right pelvic kidney (A-C-D), and a 20 x 15-millimeter stone in left renal pelvis (B)

robot-assisted laparoscopic pyelolithotomy and extracorporeal shock-wave lithotripsy (ESWL) can be used (2). But due to the abnormal anatomy, it will have more difficulties. We present a patient with a huge staghorn stone in the ectopic right pelvic kidney and a concurrent obstructive stone in his normal left kidney.

Case presentation

The patient is a 43-year-old man who was referred to the urology clinic due to left flank pain. The patient did not mention any history of kidney stones or surgery. With suspicion of urinary system stones, an ultrasound was requested for the patient. A 15-millimeter (mm) stone was reported in the left renal pelvis in the ultrasound. Also, several stones were reported in the lower and upper calyx of the left kidney with a maximum diameter of 7 mm. An abdominopelvic computed tomography (CT) scan without contrast enhancement was immediately performed on the patient. In the CT scan report, the size of the stone in the left renal pelvis was 20 x 15 mm. Also, the right kidney was seen ectopically in the pelvis, and a Staghorn stone with dimensions of 79 x 67 x 43 mm was seen inside this kidney (Figure 1). Also, a 9 mm stone was seen in the distal part of the right ureter. In terms of laboratory tests, a Hemoglobin level of 15.8 g/L, and a Creatinine level of 2.9 mg/dl were detected. GFR level was 32.5 ml/min.

The patient underwent surgery. First, the patient's distal right ureter stone was removed with the trans ureteral lithotripsy (TUL) technique, and a double-J (DJ) stent was implanted on the right ureter. Then in the prone position, PCNL surgery was performed with access from the lower calyx under the guidance of the fluoroscope. The left renal pelvis stone was completely removed. A double-J stent was placed in the left ureter and a nephrostomy was placed in the left kidney. Then, the patient underwent open pyelolithotomy for the right ectopic kidney stone in the supine position. A lower midline incision was made and the peritoneum was opened, and through that, we

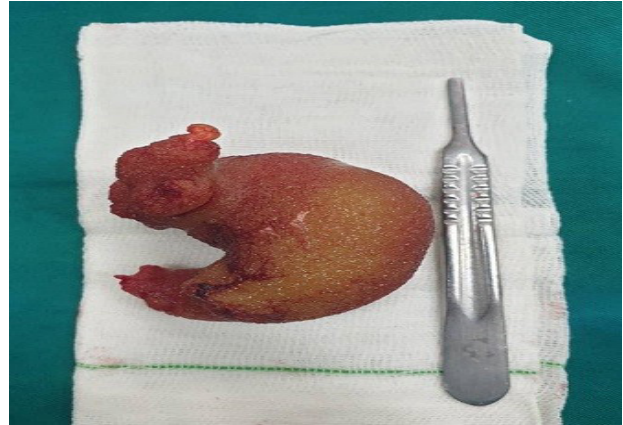


Figure 2. Right pelvic kidney stone

gained access to the retroperitoneal space. The pelvis was cut and the stone was removed (Figure 2). The pelvis was repaired with vicryl sutures and an abdominal drain was placed in the retroperitoneal space. The patient's creatinine level increased to 4 mg/dl after surgery, which decreased to 1.7 mg/dl during hospitalization. In the stone analysis after surgery, the composition of the stone was 80% citrine and 20% calcium oxalate. DJ stents of both kidneys were removed after 6 weeks.

Discussion

Today, due to progress in surgical equipment, the use of open surgeries for kidney stones is very limited. With the use of new equipment and the skill of surgeons, the rate of open surgery for kidney stones is less than 5%. In developing countries, this rate is higher (2). In the pelvic kidney, due to the location of the kidney in the pelvis and the bony structures around it, the unpredictable blood supply, the abnormal anatomy of the kidney, and the existence of the intestines around the kidney, techniques such as PCNL are very difficult and risky (3).

In kidneys with anomalies, ESWL can be a suitable option with a stone-free rate (SFR) of about 57%. But the success rate of this technique decreases in stones with a size larger than 2 cm (4). The SFR in PCNL and ESWL was lower than open surgery, and some of these patients needed re-intervention (3). In the pelvic kidney, due to the location of the kidney, performing this technique is associated with the risk of damage to the surrounding organs. Laparoscopic pyelolithotomy and robot-assisted laparoscopic pyelolithotomy have good results and are good options in centers with facilities and skilled surgeons (5).

In our patient, due to the large size of the stone, which was about 8 cm, an open pyelolithotomy was performed. Considering the patient's condition and being aware of possible risks including acute tubular necrosis (ATN), it was decided to perform the surgery on both kidneys in one stage.

Conclusions

Surgery for pelvic kidney stones should be performed using minimally invasive techniques. These techniques require the skill of the surgeon and proper surgical equipment. But in some cases, reasons such as the abnormal position of the kidney and the possibility of damage to the surrounding organs as well as the size of the stone can make open surgery unavoidable.

Authors' contributions

BJ: Conceptualization, Methodology, Visualization. SAH & AAKH: Supervision, Validation, Writing- Original draft preparation. SF: Writing- Reviewing and Editing, Software. MG: Data curation, Investigation.

Acknowledgements

Not Applicable.

Conflict of interest

The author declares that there is no conflict of interest.

Funding

The authors received no financial support for this research.

Ethical statement

Informed consent was signed by the patient. This case report is presented based on CARE guidelines.

Data availability

Data will be provided on request.

Abbreviations

ATN	Acute tubular necrosis
CT	Computed tomography
DJ	Double-J
ESWL	Extracorporeal shock-wave lithotripsy
PCNL	Laparoscopic-assisted percutaneous nephrolithotomy
TUL	Trans ureteral lithotripsy

References

1. Soltani MH, Hamedanchi S, Shakiba B, Hoshiyar H. Laparoscopic Pyelolithotomy for Management of Complete Staghorn Stone of An Ectopic Pelvic Kidney. *Urology Journal*. 2018;15(4).
2. Patandung R, Prapiska FF, Kadar DD. Open pyelolithotomy in an ectopic kidney: a case report. *Urology Case Reports*. 2021;35:101528.
3. Sharma LK, Venkatachalapathy VSS, Mishra DK, Agrawal MS. Ultrasound-guided supine mini-percutaneous nephrolithotomy in ectopic pelvic kidney. *Indian Journal of Urology: IJU: Journal of the Urological Society of India*. 2022;38(1):68.
4. Wang C, Jin L, Zhao X, Li G, Xue B. Minimally invasive treatment of an ectopic kidney stone: a case report and literature review. *Journal of International Medical Research*. 2019;47(9):4544-50.
5. Hadisuryo S, Hadi E, Danurdoro A. Open Pyelolithotomy in a Pelvic Ectopic Kidney: Case Report and Current Literature Review. *Open Access Macedonian Journal of Medical Sciences*. 2021;9(C):287-90.

Author (s) biosketches

Javanmard B, MD, Department of Urology, School of Medicine, Shahid Beheshti University of Medical Sciences, Tehran, Iran.

Email: drbabakjavanmard@gmail.com

Hojjati SA, MD, Department of Urology, Shohada-e-Tajrish Hospital, Shahid Beheshti University of Medical Sciences, Tehran, Iran.

Email: sah_hojjati@yahoo.com

Faraji S, MD, Department of Psychiatry, Roozbeh Hospital, Tehran University of Medical Sciences, Tehran, Iran.

Email: saba_faraji@yahoo.com

Garousi M, MD, Radiation Oncology Department, Iran University of Medical Sciences, Tehran, Iran.

Email: garousi.m@iums.ac.ir

Alinejad Khorram A, MD, Department of Urology, Shohada-e-Tajrish Hospital, Shahid Beheshti University of Medical Sciences, Tehran, Iran.

Email: amir.alinejad1992@gmail.com

How to cite this article

Javanmard B, Hojjati SA, Faraji S, Garousi M, Alinejad Khorram A. Open Pyelolithotomy with Concurrent Percutaneous Nephrolithotomy in a Patient with an Ectopic Pelvic Kidney. *Translational Research in Urology*. 2023 Sep;5(3):105-108.

DOI: [10.22034/TRU.2022.366280.1129](https://doi.org/10.22034/TRU.2022.366280.1129)

DOI: [10.22034/TRU.2022.366280.1129](https://doi.org/10.22034/TRU.2022.366280.1129)

URL: https://www.transresurology.com/article_175015.html

